Downloaded from http://journals.tums.ac.ir/ on Thursday, April 24, 2014

SURGERY OF SYMPTOMATIC MYOCARDIAL BRIDGING

N. Maghamipour* and N. Safaei

Department of Cardiac surgery, Shahid Madani Hospital, School of medicine, Tabriz University of Medical Sciences, Tabriz, Iran

Abstract- Myocardial bridging with systolic compression of the left anterior descending coronary artery (LAD) may be associated with myocardial ischemia. In symptomatic myocardial bridging unresponsive to medical treatment, surgical unroofing of the left LAD can be performed. Little information is available about the long-term prognosis of patients with this coronary anomaly after the surgical unroofing, so we decided to evaluate the result of this operation. A total of 26 patients underwent surgical unroofing of myocardial bridging. Patients had a myocardial bridge of at least 3 cm in length in the middle of LAD and with more than 70% compression during systole. Unroofing was performed with cardiopulmonary bypass in 16 and with off pump technique in 10 patients. In 6 patients repeat angiographies for control of myotomy were done. In one of them a nonsignificant 20% narrowing was seen. Postoperative scintigraphic and angiographic studies demonstrated restoration of coronary flow and myocardial perfusion without residual myocardial bridges under beta-stimulation in 24 patients. Two patients had residual narrowing. With off pump technique, 1 patient had perforation of the right ventricle and 1 patient underwent reoperation because of incomplete unroofing during the first operation. None of the patients with cardiopulmonary bypass technique had residual chest pain or other complications. Surgical unroofing of myocardial bridging with the aid of cardiopulmonary bypass is a safe and easy procedure with low operative risk and with excellent functional results.
© 2007 Tehran University of Medical Sciences. All rights reserved.
Acta Medica Iranica, 45(2): 111-115; 2007

Key words: Myocardial bridging, stent, left anterior descending

INTRODUCTION

Myocardial bridging defined as the transmural course of a major epicardial coronary artery, is a relatively common finding in angiographic results with a reported incidence of 0.5–35% of cases. In autopsy studies single or multiple myocardial bridging are even more frequently reported, up to 75% of cases (1). The incidence of myocardial bridging differs in different countries and is higher in Taiwanese and Japanese population (2-4). First mentioned by Reyman in 1737, bridging is considered a normal variant of coronary arteries. It involves different length of the coronary arteries and various depths in myocardial wall.

Although myocardial bridges are asymptomatic in most patients, it can causes systolic compression of the arteries and has been associated with myocardial ischemia, stunning, ventricular tachycardia, conduction disturbances, myocardial infarction, heart failure and sudden death (2, 3).

Surgical myotomy was first reported by Binet *et al.* in 1975 but little information is available about the long-term prognosis of patients with this coronary anomaly after the surgical unroofing. The purpose of this study was to evaluate the result of surgical treatment of myocardial bridging with off pump and on pump method. We have treated myocardial bridges, which caused severe stenosis in left anterior descending (LAD) artery together with myocardial ischemia with surgical unroofing of LAD.

Received: 1 Jun. 2005, Revised: 9 Nov. 2005, Accepted: 25 Apr. 2006

*** Corresponding Author:**
N. Maghamipour, Department of Cardiac surgery, Shahid Madani Hospital, School of medicine, Tabriz University of Medical Sciences, Tabriz, Iran
Tel: +98 411 3309329, 09121208341
Fax: +98 411 3309329
E-mail: maghamipour@yahoo.com

Downloaded from http://journals.tums.ac.ir/ on Thursday, April 24, 2014

MATERIALS AND METHODS

In this non randomized prospective study performed from 1999-2004 in Shahid Madani Heart Center, Tabriz University of Medical Science, 26 patients with symptomatic muscle bridging unresponsive to medical treatment were evaluated. We obtained informed written consent from all patients.

All of the patients had muscle bridges more than 3 cm in length in the middle of LAD. Preoperative patients' characteristics are shown in Table 1. All of the patients after complete evaluation with coronary angiography and echocardiography were operated with midsternotomy, and after evaluating the LAD, unroofing of LAD was done, 16 patients underwent this procedure with the aid of cardiopulmonary bypass (CPB), with pump time of average 38.8 ± 4.3 minutes and clamp time of average 23.2 ± 1.6 minutes. With a Potts scissors the muscle bridge overlying the LAD was divided. During division of the muscle cardioplegia was infused slowly to prevent LAD rupture and having a clean field during division of the bridging. Then the epicardial edges were sutured to control the bleeding points. Ten patients were operated with off pump technique and bridges were cut with surgical blade. With this technique we could not see the surgical filed clearly. In 2 patients with a significant atherosclerotic lesion proximal to the bridging, in addition to muscle bridging unroofing, internal mammary artery graft to LAD was done. About 1 week post operatively in 6 patients repeat angiography was done to evaluate the result of surgical unroofing (Fig. 1). After discharging the patients they were fallowed with ETT, echocardiography and scintigraphic studies.

Data obtained were analyzed with Student's *t* test, using SPSS 10 software.

Table 1. Pre operative patients' characteristics

Patients' characteristic	
No of patients	26
Sex, M/F (number)	16/10
Muscle bridge length (cm)	> 3
Systolic compression (percent)	> 70
Acute myocardial infarction	2 (7.69)*
Acute dissection of LAD	1 (3.84)*
Ejection fraction (mean ± SD)	52.4 ± 6.6

*Number (percent).

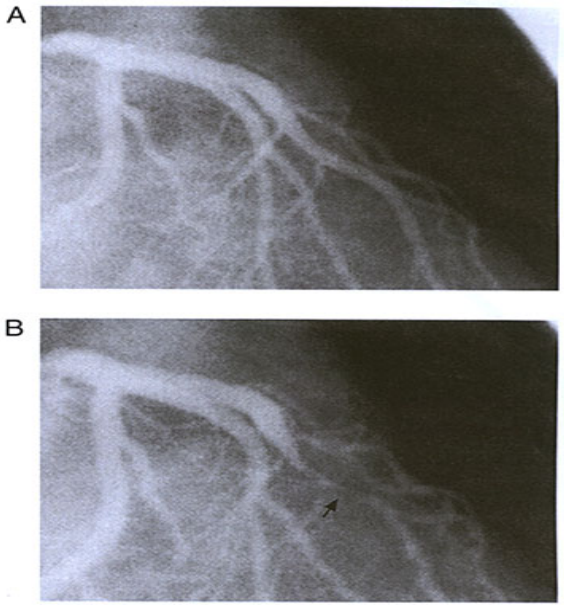

Fig. 1. LAD lumen during diastole (**A**). Typical systolic compression, arrow shows severe stenosis of the mid LAD (**B**).

RESULTS

All patients had muscle bridges on LAD, 2 patients had associated coronary artery disease proximal to LAD bridging, in addition to muscle bridging, 1 patient with spontaneous dissection proximal to the muscle bridge who developed unstable angina, and 2 patients had acute myocardial infarction. The mean age of the patients was 45.8 ± 6.3 years range from 31- 63, there were 16 males and 10 females. In angiography muscle bridges were in the middle third of LAD and with more than 70% compression during systole. Patient's ejection fractions (EF) were in the range of 40-60%, with a mean of 52.4 ± 6.6. During the operation pump times were 33-42 minutes average (38.8 ± 4.3), and clamp times were 21-36 minutes average (23.2 ± 1.6). In 1 patient right ventricle was perforated during the operation that was sutured. 1 patient had post operative bleeding which was reoperated and bleeding controlled.

One week after the operation in 3 patients with off pump method repeat angiography was done and in one of them non significant 20% systolic compression was present. But in 3 patients with CPB method operation, angiography revealed no residual narrowing. As shown in Table 2, in 1 patient with off pump method chest pain did not improve post

Downloaded from http://journals.tums.ac.ir/ on Thursday, April 24, 2014

Table 2. Operative results after unroofing of LAD artery*

Type of operation	All patients	Patients with symptoms improvement
With CPB	16 (61.53)	16 (100%)
Without CPB	10 (38.46)	9 (90%)

*Data are given as number (percent).
Abbreviation: LAD, left anterior descending; CPB, cardiopulmonary bypass.

operatively and repeat angiography showed residual narrowing which was reoperated with the aid of cardiopulmonary bypass and patient's symptoms improved.

In follow up of the patients during these five years with resting ECGs, ETT, echocardiography and scintigraphic studies, no abnormal finding were reported and did not show any specific signs of ischemia, conduction disturbances, or arrhythmias. In follow up patients did not have chest pain and had their normal physical activity.

DISCUSSION

It is hypothesized that myocardial bridges may predispose to vasospasm and limit the patient physical activity (5). Myocardial bridging in severe form produces a turbulent flow and damages the endothelium of the vessel and tends to promote or accelerate the atherosclerosis of the vessels proximal to it, so we think that we can prevent this process with unroofing the vessel (6). Myocardial bridging continues to be a subject of debate and new advances are being constantly reviewed. Fundamental issue of whether myocardial bridge unroofing or stent implantation can improve the patients who do not respond to medical therapy are evaluated, however there are only few case reports of unroofing of myocardial bridging with improvement of symptoms, and no systemic long term follow-up of these patient has yet been reported. In a review of 25 patients with stent implantation, in 7 weeks 46% of the patient required revisualization as a result of in stent stenosis or periprocedural complication (7). In another study in 11 patients with stent implantation 46% developed restenosis (8).

Stent deployment needs high insufflation's pressure and should be under intravascular ultrasound control and may cause intimal proliferation and restenosis. Coronary stent implantation may impair septal branches and angina may remain after stent implantation (9, 10). The incidence of stent thrombosis after sirolimus-eluting stent implantation was approximately 1%, which is within the expected range of bare metal stents. The discontinuation of antiplatelet therapy was strongly associated with the development of stent thrombosis in this patient population (11). Despite favorable immediate results, stent implantation in myocardial bridges has a higher in-stent restenosis rate compared to stenting in de novo atherosclerotic lesions (12).

Surgical myotomy in patients with muscle bridging and deep coronary artery has the risk of ventricular rupture, aneurysm and post operative bleeding (13, 14).

In our study, in 1 patient during the operation right ventricular rupture was sutured, and 1 patient developed post operative bleeding that was reoprated. In the follow up with echocardiography no aneurysm formation was seen in the ventricles. Mean age of the patients was (45.8±6.3) years range from 31- 63, that is consistent with other studies. Patient's ejection fractions (EF) were decreased due to stunning or fibrosis possibly because of delay in operation. In follow up, patients gained their full physical activity and their symptoms resolved.

2 patients referred because of acute myocardial infarction. It is hypothesized that myocardial bridges in patients with a recent myocardial infarction may predispose to vasospasm; therefore, testing for vasospasm in patients with otherwise normal coronary angiograms is suggested. 1 patient had coronary artery dissection proximal to the bridging and 2 patients had coronary atherosclerosis proximal to the bridging which is due to turbulent flow in this area. We recommend that surgery be done prior to these complications with the aid of cardiopulmonary bypass (CPB). In our series 16 patients were operated with CPB and without any complication or mortality. Only 1 patient with off pump method of operation had residual stenosis that underwent reoperation. Case reports from other centers with off pump method of operation, good results had been obtained (15, 16). In follow up of these patients there

Downloaded from http://journals.tums.ac.ir/ on Thursday, April 24, 2014

was no mortality, no recurrence of symptoms and no other complications. There was 100% cure rate with CPB method of operation. With regard to restenosis and septal branch occlusion and difficulty in stent implantation and lack of experience of cardiologists in this center to implant the stent under intravascular ultrasound, our data suggest that unroofing of myocardial bridging with the aid of cardiopulmonary bypass is a safe, easy, low risk and effective procedure to treat symptomatic myocardial bridging unresponsive to medical therapy. This technique is extremely simple, eliminates the need of long life drug therapy and restores patient's full physical activity. We recommend that this procedure be performed routinely in patients unresponsive to medical therapy in other heart centers in Iran.

1- In symptomatic muscle bridges unresponsive to medical treatment muscle bridges unroofing is a safe and easy procedure that convert the turbulent flow to linear flow, so preventing the endothelial damage.

2- Use of cardiopulmonary bypass in this procedure creates a clean operative field that results in lower post operative complication.

Acknowledgements

We thanks Dr. Safaeian and Miss Salek and appreciate the authorities of Tabriz University of Medical Science in this research.

Conflict of interests

The authors declare that they have no competing interests.

REFERENCES

1. Prendergast BD, Kerr F, Starkey IR. Normalisation of abnormal coronary fractional flow reserve associated with myocardial bridging using an intracoronary stent. Heart. 2000 Jun; 83(6):705-707.
2. Chen JS, Lin CL. Myocardial Bridging. Tzu Chi Med J. 2002; 15: 357-362.
3. Marchionni N, Chechi T, Falai M, Margheri M, Fumagalli S. Myocardial stunning associated with a myocardial bridge. Int J Cardiol. 2002 Jan; 82(1):65-67.
4. Chan AK, Rak J, Berry L, Liao P, Vlasin M, Weitz J, Klement P. Antithrombin-heparin covalent complex: a possible alternative to heparin for arterial thrombosis prevention. Circulation. 2002 Jul 9; 106(2):261-265.
5. Guo LJ, Tan TT, Mao JM. [Clinical manifestation and prognosis of myocardial bridge]. Zhonghua Yi Xue Za Zhi. 2003 Apr 10; 83(7):553-555. Chinese
6. Haager PK, Schwarz ER, vom Dahl J, Klues HG, Reffelmann T, Hanrath P. Long term angiographic and clinical follow up in patients with stent implantation for symptomatic myocardial bridging. Heart. 2000 Oct; 84(4):403-408.
7. Bayes A, Marti V, Auge JM. Coronary stenting for symptomatic myocardial bridging. Heart. 1998 Jul; 80(1):102-103.
8. Stables RH, Knight CJ, McNeill JG, Sigwart U. Coronary stenting in the management of myocardial ischaemia caused by muscle bridging. Br Heart J. 1995 Jul; 74(1):90-92.
9. Klues HG, Schwarz ER, vom Dahl J, Reffelmann T, Reul H, Potthast K, Schmitz C, Minartz J, Krebs W, Hanrath P. Disturbed intracoronary hemodynamics in myocardial bridging: early normalization by intracoronary stent placement. Circulation. 1997 Nov 4; 96(9):2905-2913.
10. Agirbasli M, Martin GS, Stout JB, Jennings HS 3rd, Lea JW 4th, Dixon JH Jr. Myocardial bridge as a cause of thrombus formation and myocardial infarction in a young athlete. Clin Cardiol. 1997 Dec; 20(12):1032-1036.
11. Roul G, Sens P, Germain P, Bareiss P. Myocardial bridging as a cause of acute transient left heart dysfunction. Chest. 1999 Aug; 116(2):574-580.
12. Jeremias A, Sylvia B, Bridges J, Kirtane AJ, Bigelow B, Pinto DS, Ho KK, Cohen DJ, Garcia LA, Cutlip DE, Carrozza JP Jr. Stent thrombosis after successful sirolimus-eluting stent implantation. Circulation. 2004 Apr 27; 109(16):1930-1932.
13. Kursaklioglu H, Barcin C, Iyisoy A, Kose S, Amasyali B, Isik E. Angiographic restenosis after myocardial bridge stenting. Jpn Heart J. 2004 Jul; 45(4):581-589.
14. Tumer C, Neyyir T, Sadik E, Kaan K, Ozlem K, Hakki A. Myocardial bridging surgery performed by off pump technique: a report of two cases. Journal of Ankara Medical School. 2002; 24: 211-214.

15. Hillman ND, Mavroudis C, Backer CL, Duffy CE. Supraarterial decompression myotomy for myocardial bridging in a child. Ann Thorac Surg. 1999 Jul; 68(1):244-246.

16. Katznelson Y, Petchenko P, Knobel B, Cohen AJ, Kishon Y, Schachner A. Myocardial bridging: surgical technique and operative results. Mil Med. 1996 Apr; 161(4):248-250.

Downloaded from http://journals.tums.ac.ir/ on Thursday, April 24, 2014