Downloaded from http://journals.tums.ac.ir/ on Saturday, March 08, 2014

Case Report

Iran J Ped
Sep 2007; Vol 17 (No 3), Pp:297-301

Neonatal Subgaleal Hemorrhage
"A fatal complication of vacuum extraction delivery"

Fatemeh Nasseri [*1] MD; Zohreh Badiei[1] MD

1. Neonatologist, Department of Pediatrics, Isfahan University of Medical Sciences, IR Iran

Received: 05/02/07; Revised: 27/04/07; Accepted: 13/06/07

Abstract

Objective: Neonatal subgaleal hemorrhage is a rare but potentially lethal complication of instrumental delivery, particularly vacuum extraction. It is often underreported and underdiagnosed. The prevalence of subgaleal hemorrhages varies from 0.04 to 0.15% of all deliveries. We describe two cases of severe subgaleal hemorrhage (SGH) and review the key elements of identification and treatment.

Case report: The first case was a female neonate with birth weight 2220gr that was born by vacuum assisted vaginal delivery. At birth, the infant was pale, flaccid with no respiratory effort. She was grossly pale with poor perfusion, lethargic, decreased muscle tone, anemia, and hypovolemic shock. On her head a large fluctuant swelling was seen. She died at 20th hours of age. The second case was a full term male neonate that was born with cesarean section after an unsuccessful 2 to 3 time vacuum extraction. At birth the infant was limp, cyanotic with weak respiratory effort. After 7th hours, a severe fluctuant swelling was found on his head with head circumference of 38.5 cm and ecchymosis around his orbits. He developed anemia and seizure. After successful treatment, he was released from hospital.

Conclusion: Increased awareness of SGH should lead to earlier identification, referral and treatment, with resultant improved outcomes.

Key Words: Neonate, Subgaleal hemorrhage, Vacuum delivery, Anemia

Introduction

Advancements in obstetrical management in the last several decades have significantly decreased the incidence of birth trauma. Despite the decline in the incidence of birth trauma, injury during the birth process continues to be a significant contributor to mortality and morbidity in neonates[1, 2].

Subgaleal hemorrhage (SGH) is a serious but rarely seen form of bleeding that can occur as a complication to vacuum–assisted delivery. SGH is a collection of blood in the soft tissue space between the galea aponeurotica and the

*** Correspondence author;**
Address: Division of Neonatology, Alzahra Hospital, Isfahan University of Medical Sciences, Isfahan, IR Iran
E-mail: nasseri@med.mui.ac.ir

Downloaded from http://journals.tums.ac.ir/ on Saturday, March 08, 2014

periosteum of skull. This subaponeurotic space may hold as much as 260 ml of blood, therefore can lead to severe hypovolemia and cause death in 20% to 60% of patients[2,3,4,5].

The prevalence of subgaleal hemorrhages varies from 0.04 to 0.15% of all deliveries. Moderate to severe forms of SGH is reported to be approximately 1.5 per 10000 births[3, 6].

This article describes two typical cases of severe SGH in newborns who were admitted to NICU in Isfahan University hospitals, to emphasis that early recognition and treatment of this condition is critical.

Case Presentation

Case 1: A 2220-gram female was born at 36 week's of gestation to a primigravida mother by vacuum assisted vaginal delivery. Apgar scores were 2, 5, and 7 at 1, 5, and 10 minutes, respectively. At birth, the infant was pale, flaccid with no respiratory effort. The infant was resuscitated with endotracheal intubation, positive pressure ventilation with 100% oxygen and external cardiac massage. At the time of admission to the NICU the infant was described to be grossly pale with poor perfusion, lethargic with decreased muscle tone and shock in appearance; blood pressure was 42/21 mmHg. Peripheral pulses were weak. Blood gas analysis revealed metabolic acidosis. On her head a large fluctuant swelling was noted. Hemoglobin value was 10.6 at 3 hours of age. The infant received multiple boluses of normal saline, fresh frozen plasma, and packed red blood cells, together with broad-spectrum antibiotics, dopamine and sodium bicarbonate infusion. Despite full neonatal intensive care baby remained hypotensive with a bleeding tendency, a persistent metabolic acidosis, and no urine output. She died 20 hours after birth.

Case 2: A 3600-gram male infant was born at term by C/S after 2 to 3 unsuccessful attempts of vacuum extraction. Apgar scores were 3, 5, and 7 at 1, 5, and 10 minutes, respectively. At birth the infant was limp, cyanotic with weak respiratory effort. Airway suction, positive pressure ventilation with bag and mask and 100% oxygen was applied. The infant was admitted to the regular nursery with the recommendation of close observation and monitoring with pulse oxymetry. At about 1 hour of life he had multi focal clonic seizures. Fluid, glucose and antibiotics were given, and then he was transferred to our NICU at 7th hours of life. On arrival, we noted a severe fluctuant swelling on his head and ecchymosis around his orbits; head circumference measured 38.5 cm (Fig 1 and 2).

He developed anemia (Hb 11g/dl) requiring red blood packed cells transfusion, and jaundice requiring phototherapy. He received anti-convulsant drugs for seizures. After initial stabilization, brain CT showed abundant epicranial blood and diffuse cerebral edema. (Fig 3). Prior to discharge EEG showed multiple seizure foci. He was discharged on the 10th day of life advising parents to appear regularly for neurological follow up.

Discussion

Subgaleal hemorrhage is potentially fatal accumulations of blood beneath the galea apo-neurotica of the scalp in the newborn. Most cases of SGH have been associated with the use of vacuum extraction. Chadwick et al reported 37 infants who were admitted with SGH over a period of 24 years from 1970 to 1993. All but one of the neonates had instrumental delivery [3]. Ng et al estimated that the risk of subgaleal bleeding was 60 times more likely with a vacuum extractor than with other modes of childbirth[7]. In Kilani et al study, 91.2% of cases with SGH had instrumental delivery, mostly by vacuum or vacuum followed by forceps application[4].

The fragility and delicate nature of the newborn infant's scalp tissues render them vulnerable to injury by either friction of the fetal scalp against infant's scalp tissues render them vulnerable to injury by either friction of the fetal scalp against the application of forceps or suction cups. The risk of bleeding after vacuum extraction is increased in primipara, severe dys-tocia, malposition of the fetal head and multiple, forceful or prolonged use of the vacuum suction, fetal macrosomia, prematurity and male sex[8,9,10].

Downloaded from http://journals.tums.ac.ir/ on Saturday, March 08, 2014

Fig 1- Ecchymotic discoloration around orbits in one of the our patients with Subgaleal hemorrhage

Fig 2- A sever fluctuant swelling on the head of our patient with Subgaleal hemorrhage

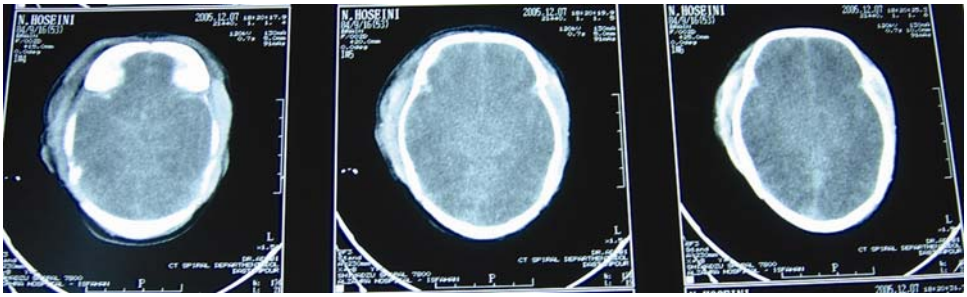

Fig 3- Brain CT scanning was demonstrated abundant epicranial blood and diffuses cerebral edema

Downloaded from http://journals.tums.ac.ir/ on Saturday, March 08, 2014

In this article, the first baby was born near term, prematurity might have increased the risk of bleeding. She could not be saved despite massive volume resuscitation. The second case had the vacuum applied 2 or 3 times, which should have increased staff vigilance for SGH.

The clinical signs of SGH include presence of a fluctuating mass that crosses suture lines, fontanels or both and evidence of hypovolemic shock[2,9]. Pallor and hypotonicity could be the only early systemic signs of SGH. The amount of blood loss in SGH is often underestimated and can continue to increase for several days after birth[11,12]. Later in the course of SGH, signs of cerebral irritation appear and convulsions can occur [9]. A brain CT scan, or magnetic resonance imaging (MRI) should be considered for subgaleal bleeding confirmation [13,14].

Early diagnosis, careful monitoring, and prompt treatment to avoid hypovolemic shock are the key to improving outcome. Monitoring should include a minimum of 8 hours observation with hourly recordings of vital signs for all babies after difficult vacuum extractions. The most important risk factors for death in babies with SGH are: decrease in hematocrit more than 25% of the baseline value at birth requiring urgent blood transfusion in the first 12 hours, and association with significant birth asphyxia [15,16]. Severe hypovolemia and coagulopathy are the most common clinical problems associated with mortality. Prognosis depends on the severity of the hemorrhage; with early recognition and aggressive volume resuscitation full recovery is possible and long-term outlook for survivors is good [17].

Coagulopathy due to hypoxy–ischemia and release of brain thromboplastin may exaggerate the blood loss in the SGH [4,18,19]. In the first case we could not be absolutely sure that blood loss or birth hypoxic ischemic encephalopaty was the prime cause of death.

The majority of SGHs are preventable. Education and training on the proper use of vacuum for instrumental delivery is vital to reduce the incidence of this condition [16,20]. In addition, pediatrician must be careful in the assessment of neonates after instrumental delivery even in the absence of a fluctuant mass soon after birth, and particularly when there has been hypoxic ischemic insult or shock in the newborn.

Conclusion

Neonatal SGH is a rare and potentially life-threatening complication of delivery. Increased awareness of SGH should lead to earlier identification, referral and treatment, with resultant improved outcome.

References

1. Medlock MD, Hanigan WG, Neurologic birth trauma. Intracranial, spinal cord and brachial plexus injury. Clin Perinatol.1997; 24(4):845-57.
2. Parker LA. Part 1: early recognition and treatment of birth trauma: injuries to the head and face. Adv Neonatal Care. 2005; 5(6):288-97.
3. Chadwick LM, Pemberton PJ, Kurinczuk JJ. Neonatal subgaleal hematoma: associated risk factors, complications and outcome. J Paediatr Child Health. 1996; 32(3):228-32.
4. Kilani RA, Wetmore J. Neonatal subgaleal hematoma: presentation and outcome--radiological findings and factors associated with mortality. Am J Prinatol. 2006;23(6): 41-8.
5. Hall SL. Simultaneous occurrence of intracranial and subgaleal hemorrhages complicating vacuum extraction delivery. J Perinatol. 1992;12(2):185-7.
6. Davis DJ. Neonatal subgaleal hemorrhage: diagnosis and management. CMAJ. 2001; 164(10):1452-3.
7. Ng PC, Siu YK, Lewindon PJ. Subaponeurotic hemorrhage in the 1990s; a 3-year surveillance. Acta Paediatr. 1995; 84(9):1065-9.

Downloaded from http://journals.tums.ac.ir/ on Saturday, March 08, 2014

8. Boo NY, Foong KW, Mahdy ZA, Yong SG, Jaafar R. Risk factors associated with subaponeurotic haemorrhage in full-term infants exposed to vacuum extraction. BJOG. 2005;112(11):1516-21.

9. Plauche WC. Subgaleal hematoma. A complication of instrumental delivery. JAMA. 1980;244(14):1597-8.

10. Gobremariam A. Subgaleal hemorrhage: risk factors and neurological and developmental outcome in survivors. Ann Trop Paediatr. 1999;19(1):45-50.

11. FDA Public Health Advisory: Need for Caution When Using Vacuum Assisted Delivery Devices. Rockville, MD: U.S. Food and Drug Administration. May 21, 1998.

12. Cavlovich FE. Subgaleal hemorrhage in the neonate. J Obstet Gynecol Neonatal Nurs. 1994;24(5):397-404.

13. Ilangan NB, Weyhing BT, Liang KC. Radiological case of the month. Neonatal subgaleal hemorrhage. Arch Pediatr Adolesc Med. 1994;148(1):65-6.

14. Hopkins RE, Inward C, Chambers T, et al. Sub-aponeurotic fluid collections in infancy. Clin Radiol. 2002;57(2):114-6.

15. Amar AP, Aryan HE, Meltzer HS, et al. Neonatal subgaleal hematoma causing brain compression: report of two cases and review of the literature. Neurosurgery 2003; 52(6):1470-4.

16. Uchil D, Arulkumaran S. Neonatal subgaleal hemorrhage and its relationship to delivery by vacuum extraction. Obstet Gynecol Surv. 2003;58(10):687-93.

17. Gebremariam A. Subgaleal hemorrhage: risk factors and neurological and developmental outcome in survivors. Ann Trop Paediatr.1999;19(1):45-50.

18. Keimowitz RM, Annis BL. Disseminated intravascular coagulation associated with massive brain injury. J Neurosurg. 1973; 39(2):178-80.

19. Doumouchtsis SK, Arulkumaran S. Head injuries after instrumental vaginal deliveries. Curr Opin Obstet Gynecol. 2006; 18(2):129-34.

20. Chessells JM, Wigglesworth JS. Coagulation studies in severe birth asphyxia. Arch Dis Child. 1971;46(247): 253-6.